



INTERDISCIPLINARIA ARCHAEOLOGICA

NATURAL SCIENCES IN ARCHAEOLOGY

homepage: <http://www.iansa.eu>



Traces of Dissection on Human Skeletal Remains of the First Half of 19th Century from Ostrava, Czech Republic

Michal Živný^{a*}, Zbyněk Moravec^b

^aDepartment of Biology and Ecology, Faculty of Science, University of Ostrava, Chitussiho 10, 710 00 Ostrava, Czech Republic

^bOstrava Museum, Masarykovo náměstí 1, 728 41 Ostrava, Czech Republic

ARTICLE INFO

Article history:

Received: 1st December 2016

Accepted: 28th December 2016

Key words:

Ostrava
graves
human skeletal remains
archaeology
anthropology
archives
Early Modern Times
dissection

ABSTRACT

Rescue archaeological excavation in Puchmajerova Street, Ostrava, Czech Republic, has resulted in the discovery of approximately 40 graves dating back to the Early Modern Period. One of the graves, number 841, connected with the last stage of the cemetery's existence, has provided human bones in a very poor state of preservation. These have been anthropologically analysed and subsequently interpreted as the remains of a woman who died in her young adult life (20–25 years). The skeleton number 841 shows traces of dissection-like intervention in the right parietal bone and squama of the frontal bone, which has proved to be a key factor for subsequent investigations. Based on archaeological findings (the dating and grave inventory), anthropological assessment (sex, age and dissection traces), and written sources (registers of deaths), we have been able to identify this skeleton as the remains of the Ostrava burgher Marianna Máchová (1817–1837), who committed suicide in 1837.

1. Introduction

In 2007 a rescue archaeological excavation in Puchmajerova Street, Ostrava, Czech Republic, was realized in connection with reconstruction work on underground utilities. The excavation resulted in the unearthing of circa 40 graves which date back to the Early Modern Period. The cemetery was founded in 1586 (as a solution to the increased mortality due to the plague epidemic) and was used until 1843 (or 1852). Between 1785 and 1843 it was the main burial ground for the inhabitants of Moravská Ostrava and some affiliated villages. Within the cemetery area, St. Luke's chapel was built in the last phase of the cemetery's existence, the chapel surviving the abolition of the cemetery by nearly half a century. The excavated skeletal material was exhumed and studied by anthropologists. The major results of this archaeological and anthropological research have already been published (Moravcová *et al.* 2015; Moravec *et al.* 2014; Živný *et al.* 2011).

The conclusions reached by the evaluation of the archaeological findings fully correspond with our knowledge of burial rites in the Early Modern Period – the cemetery represents a typical Post-Medieval burial ground and is comparable with dozens of parallel examples in Moravia and neighbouring regions (Králíková 2007; Rubínková 1999; Unger 2006). Thorough standard “traditional” anthropological research of the human skeletal remains revealed no extraordinary outcomes concerning the demographic characteristics of the population. Nevertheless, a revision of the anthropological examination of the individual in grave number 841 has brought some quite unique findings relating to cause of death, which has proved to be a key point for the further research undertaken. With few exceptions (rulers, generals, clerics, *etc.*), the dead buried in graves in past centuries are fully anonymous persons whose lives we may only get to know partially and indirectly by means of archaeological and anthropological (or other natural-science-based) research. As we shall see, the skeleton exhumed from grave number 841 is one of those exceptions. Based on the interplay of several coincidences, it has been possible to

*Corresponding author. E-mail: michal.zivny@osu.cz



Figure 1. Skeleton number 841: field excavation. Taken from Moravec *et al.* 2014.

identify the skeleton with a known person, and subsequently to look deeper into her life by means of the available written sources. Thus the skeletal remains from grave number 841 play a major role in this paper. The primary goal is to refer to the rare and unusual archaeological find of a postmortem invasion into the skull. The identification of the skeletal remains with a real historical person who has provided recorded information on the said postmortem manipulation is regarded as proof as to the correctness of our observations.

2. Material and methods

2.1 Archaeological background

Grave number 841 was situated in the very latest (most recent) group of burials at our cemetery. It is dated back to

the period 1785–1843 and, in agreement with the funeral practices of that times, it was placed in a single line. The eastern (or lower) half of the grave (and skeletal remains) did not still exist at the time of our archaeological excavation, having been already removed by earlier building activities on the cemetery site. Thus only the western (or upper) half of the grave had been preserved for subsequent research (Figure 1). The grave was oriented in a NW–SE direction. There were poorly preserved human skeletal remains in a stretched supine position in the grave pit, with the upper extremities bent at the elbow joints and hands laid on the chest. Furthermore, the remains of a wooden coffin were detected around the skeleton (Moravec *et al.* 2014, 68–69). In contrast to the condition of the skeletal remains themselves, these wooden residues represent the best preserved coffin remnants at our cemetery. The coffin was originally closed by iron nails and was

probably inlaid by textiles (Moravcová *et al.* 2015, 285). The grave goods consisted of two items of a devotional character (crosses, one on the chest, the other in the palm of the hand, presumably), which represent very common components of Early Modern Period graves (Králiková 2007; Moravcová *et al.* 2015, 285–287; Rubinková 1999). The objects of the grave's inventory and other aspects of the burial rites do not predict the biological features of the deceased (*e.g.* gender),

but do indicate higher social status.

2.2 State of preservation

The skeletal remains in grave number 841 have been preserved poorly overall, both in quantity and quality. We only have around 15–20% of the bone mass of the entire skeleton (Figure 2). All preserved bones (or fragments thereof) were found in their normal anatomical position. The upper half

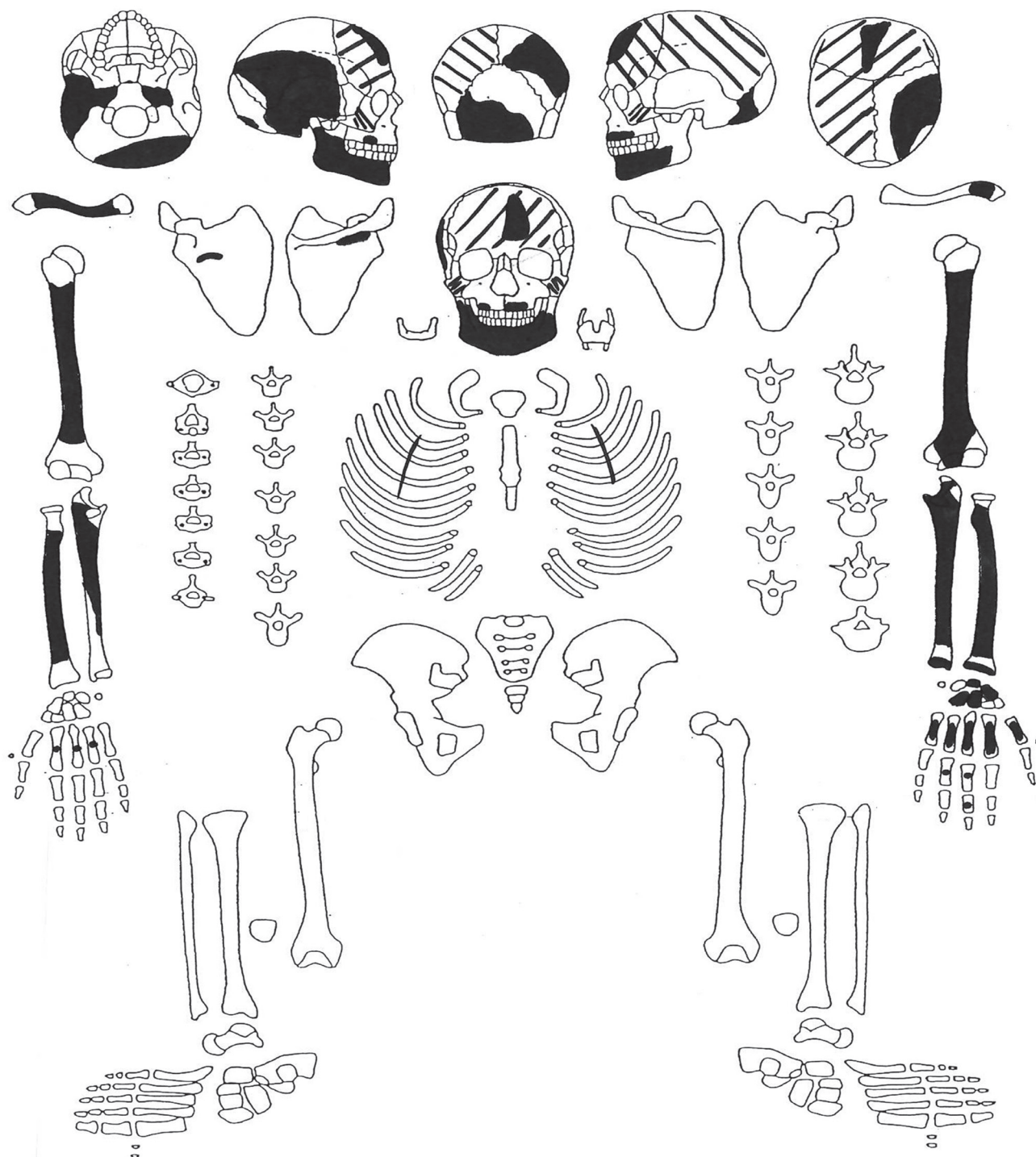


Figure 2. Skeleton number 841: depiction of available parts. Drawn by Michal Živný. Chart made by University of Göttingen (Zentrum Anatomie, M. Schultz).

of the body (especially the trunk) was strongly affected by post-depositional taphonomic processes (probably due to decaying wood from the coffin remnants), which resulted in almost the complete disintegration of the spine (vertebrae) and chest bones (ribs), the disappearance of most of the skull, and the partial disturbance of the bones of upper extremities. The lower half of the body (lumbar and sacral spine and lower extremities) was fully damaged and removed by earlier building activity in the area of the former cemetery during the 20th century.

2.3 Brief summary of preserved bones

2.3.1 Trunk skeleton

Only around 1% of bone volume has been preserved in the case of trunk bones (only a few tiny fragments of ribs and vertebrae are available).

2.3.2 Skull

In the case of the cranium (excluding lower jawbone), around 30–40% of bone mass has been preserved. Despite this, the surviving parts of the skull provide a very important source of information concerning the anthropological features of the skeleton. In the neurocranium, remnants of cranial vault bones in particular are available, while bones of the skull base have been preserved only slightly. We have a large part of the right parietal bone, part of the *squama*, *pars petrosa*, *pars tympanica* and a complete *processus mastoideus* of the right temporal bone, a *pars petrosa* of the left temporal bone, a few fragments of the frontal and occipital bones, and a few tiny fragments of hardly classifiable cranial vault bones. As regards the facial skeleton, only two fragments of upper jawbones (to the extent of alveolar arches) and parts of both cheek bones are available.

2.3.3 Lower jawbone

The lower jawbone has been preserved in the form of a larger fragment comprising around 70% of its bone mass. This fragment contains a part of the corpus and *ramus dexter* (with incompletely preserved both coronoid and articular processes).

2.3.4 Teeth

In addition, we have almost all the permanent teeth of both jawbones available, excluding the third molars. Only the right and left upper first molars were still fixed in the tooth alveols, other teeth had already fallen out (postmortem) by the time of exhumation.

2.3.5 Right upper extremity

This part of the body has been preserved to the extent of around 60–70% of bone mass volume. The following bones and their fragments are available:

- *clavicula*: approximately 80% of the bone mass (body without sternal and acromial end),
- *scapula*: approximately 5–10% of the bone mass (area of attachment of *spina scapulae*),

- *humerus*: approximately 80% of the bone mass (diaphysis proximally broken off in area of *collum chirurgicum* and distally under the point of the shortest circumference; neither of the epiphyses were available),
- *radius*: approximately 80% of the bone mass (diaphysis proximally broken off in area of *collum radii* and distally slightly above the connection point with the distal epiphysis; neither of the epiphyses were available),
- *ulna*: about 60% of the bone mass (diaphysis proximally broken off at level of *incisura trochlearis*) and distally slightly below the midpoint of the bone; neither of the epiphyses were available),
- *ossa manus*: three metacarpal bone fragments.

2.3.6 Left upper extremity

This has also been preserved to the extent of around 60–70% of bone mass volume. The following bones and their fragments are available:

- *clavicula*: approximately 10% of the bone mass (small portion close to the acromial end),
- *humerus*: approximately 80% of the bone mass (diaphysis proximally broken off in area of *collum chirurgicum*; distally an accreted portion of the epiphysis with part of *trochlea* has been preserved; the proximal epiphysis was not available),
- *radius*: approximately 90% of the bone mass (2 fragments – diaphysis proximally broken off in area of *collum radii* and part of the distal portion of the diaphysis with accreted epiphysis with carpal articular surface; the proximal epiphysis were not available),
- *ulna*: approximately 90% of the bone mass (2 fragments – diaphysis proximally broken off in area of *incisura trochlearis* and *olecranon* and part of the distal portion of the diaphysis with accreted epiphysis),
- *ossa manus*: four carpal bones (*os scaphoideum*, *os lunatum*, *os capitatum* and *os hamatum*) and all five almost complete metacarpal bones.

2.4 Methods of anthropological assessment

Human skeletal remains from grave number 841 underwent laboratory treatment and subsequent anthropological examination, which comprised of osteometric analysis, assessment of sex as well as age at death, estimation of body height and, subsequently, description of peculiarities and their interpretation in the context of archaeological observations and historical sources. The state of preservation of the skeletal remains prevented an extensive metric analysis of the bones. The skull is completely immeasurable (it was not possible to reconstruct it in terms of preserved fragments). Only the long bones of the upper extremities, owing to their relatively favourable state of preservation, have provided several significant osteometric results, which could be used for the assessment of sex and body height. Basic anthropological characteristics, such as sex and age, have been researched using standard macroscopic procedures

of skeletal anthropology (summarized, for example, in Buikstra, Ubelaker 1994; Stloukal 1999). Methods used for particular steps of the anthropological determination are specified in the relevant chapters. In spite of the available bones being in such an unsatisfactory state, an attempt to identify the skeletal remains with a specific historical figure was carried out. In order to enhance the plausibility of the anthropological results needed for the drawing of persuasive conclusions, the results of the anthropological analysis are described in depth in the following.

3. Results

3.1 Assessment of sex

Despite the poor preservation of the skeleton as a whole and the absence of pelvic bones, an assessment of the individual's sex was carried out with relatively highly reliable results. Sex assessment was based on an evaluation of sexually-dimorphic traits in several well-preserved bones of the skull and upper extremities both by morphoscopic and morphometric procedures.

3.1.1 Morphoscopic assessment of the skull

For sex diagnosis of the skull, a morphoscopic evaluation according to Acsádi, Nemeskéri (1970) was carried out. Because of the considerably incomplete state of preservation of the skull (only a few bone fragments available), it was not possible to employ quantification of morphoscopic traits in our analysis. We based our assessment only on several separate sexually dimorphic traits without the possibility of a complete and contextual assessment of the skull as a whole. *Processus mastoideus* of the right temporal bone is very small and shows feminine or hyper-feminine development. The lower jawbone, too, is small and gracile – again providing the conclusion for an assignment as feminine or hyper-feminine. Thus both these traits demonstrate the female sex of our individual with a high degree of reliability. Moreover, we could also evaluate the area of the *protuberantia occipitalis externa* and part of the *planum nuchale* on the preserved fragment of occipital bone, which, on the one hand, seems to be relatively robust, but, on the other, has a quite smooth surface, lacking any emphasized muscle insertions. However, because only the partially preserved occipital bone was available, it is not possible to use this for the purpose of sex assessment without some contextual evaluation of the rest of the skull; the bone itself does not disprove the unambiguous feminine classification of the skull.

3.1.2 Morphometric assessment of the arm bones

The arm bones were examined using morphometric methods (Černý 1971; Černý, Komenda 1980). A female (or hyper-feminine) sex assignment is obvious due to the visually apparent small size and overall conspicuous gracility of the bones. Using the arm bones we obtained the most important data. Despite the incomplete preservation of the left *humerus*, a fairly accurate estimation of its original length

could be assessed. The maximum length of the left *humerus* (H1) reaches approximately 275–285 mm. The output from the determination procedure indicates a feminine or hyper-feminine character for this trait. Because of the missing epiphyses (or epiphyseal ends), neither of the arm bones could be used for sex diagnosis based on evaluation of robusticity traits such as dimensions (diameters and/or circumferences) of their heads (measures H8, H9 and H10), which would possibly provide more reliable outputs than the linear dimensions. Nevertheless, in the case of the left *humerus* the midpoint of the diaphysis could be defined; its largest diameter (H5) measures 17.5 mm and the narrowest diameter (H6) 14.0 mm. The smallest circumference of the diaphysis (H7) reaches 47 mm. In the case of the right *humerus*, an independent estimate of its biggest length (and thus the definition of its midpoint and diameters of the diaphysis) would be imprecise, but it was possible to determine the smallest circumference of the diaphysis (H7) which reaches a measure of 49 mm. These values significantly indicate the hyper-feminine character of the arm bones.

The authors of the aforesaid methods introduced a procedure for sex assessment using a collection of Czech skeletal material from the 1930s, which is about a century more recent than the skeleton from grave number 841. Therefore we can assume that the dimensions of arm bones in the authors' collection were affected by the influence of the secular trend. However, it did not reach such a rapid rate as later during the 20th century (see Vignerová, Bláha 1998; Vignerová *et al.* 2006), so our values showing hyper-feminine metric traits can be considered as very reliable for determination of the individual from grave number 841 and its classification to a female sex category.

3.1.3 Summary of the sex assessment

All applicable methods for sex assessment strongly support the conclusion that the sex of the individual from grave number 841 is female with a high degree of reliability. In spite of the poor state of the skeletal remains, we can regard this conclusion as fully applicable for historical interpretations.

3.2 Assessment of age at death

The individual in grave number 841 died as an adult, as evidenced by the erupted permanent teeth and finished fusion of diaphyses and distal epiphyses of the forearm bones. As is known, a more accurate assessment of the age at death of adults is significantly complicated or precluded, especially above the age of 25 (Brůžek 2008; Piontek, Weber 1990), even in cases of more completely preserved skeletons. As mentioned above, our individual was exhumed in a poor state of preservation – both in its quantitative and qualitative aspects. In spite of the skeleton's poor condition, as in the sex assessment some preserved bone fragments allow us to achieve relatively accurate results for age assessment.

3.2.1 Dental wear

Our dental sample consists of well preserved permanent teeth coming from both sides of the upper and lower jawbones.

The state of the teeth thus enables an evaluation of their wear within a context of complex dentition, as pictured in the methodology by Lovejoy (1985). As a matter of fact, the lack of or very slight dental wear of the teeth of our skeleton gives evidence for a lower age category in terms of adult age, within a range of approximately 15–25 years.

3.2.2 Suture obliteration

The cranial vault bones were available only as smaller or larger fragments in our skeletal sample, making it impossible to assess the state of suture obliteration in the skull as a whole (see Linc 1971; Meindl, Lovejoy 1985). Although some small residues of preserved sutures (e.g. *sutura parietomastoidea*, a tiny section of *sutura lambdoidea*, and short fragments of *sutura coronalis*) show no traces of obliteration, indicating a relatively lower age, this finding is limited due to the impossibility of assessing the complete cranial vault; rather, they are usable only in support of the other results of age assessment.

3.2.3 Skeleton maturation

The most important evidence for the inclusion of our skeleton as being in the youngest stage of adulthood is the persistent and clearly visible line resulting from the finished fusion of the diaphysis and distal epiphysis of the left *ulna* and left *radius*. In our experience, ossification lines as a result of diaphyseal-epiphyseal (or diaphyseal-apophyseal) fusion tend to be conspicuously visible for a few more years after the termination of growth plate ossification. Either way, the complex fusion occurs at the end of juvenile or start of adult age. According to Krogman and Iscan (Krogman, Iscan 1986) and other authors, in the case of forearm bones, the beginning of ossification of the distal growth plate occurs at the age of 18–19 years and complete amalgamation and maturation of the *ulna* comes after the 20th year of life. According to Stewart (1979) and Schwartz (1995), in the case of the *radius*, the complete fusion of the diaphysis and distal epiphysis occurs in adults aged over 20 years (most frequently 20–23 years), and a bit later, at an age of just under 25 years, in the case of the *ulna*.

3.2.4 Summary of the age assessment

Based on the partial results mentioned above, we can conclude that the skeleton from grave number 841 belongs to that of an adult who died in the youngest phase of adult life (adultus I), at the age of ± 20 years, or within the category of 20–25 years.

3.3 Assessment of body height

Body height has been assessed using the estimated length of the left humerus (275–285 mm, see above). According to the Sjøvold equations (Sjøvold 1990), the body height of our individual falls within the range 146–151 cm. The equations of Bach (Bach 1965) resulted in slightly higher values, within 152–159 cm. Using the equations of Černý and Komenda (Černý, Komenda 1982) brings a value of 146–150 cm. All these outputs work with an accuracy of \pm

4–5 cm. The first-mentioned approach is independent of the sex of the skeletal remains, whereas the latter two methods work from the premise that our skeleton is of female sex (see above). Most frequently, the complex results of the aforesaid methods range between 146 and 159 cm. By today's standards – paying regard to the sex of our individual – such values have to be categorized as below-average stature (the average adult body height of contemporary women in the Czech Republic is approx. 167 cm). Given the context of the first half of the 19th century, our result falls within the values of medium-height or slightly under-medium-height (classification by Martin, Saller 1957).

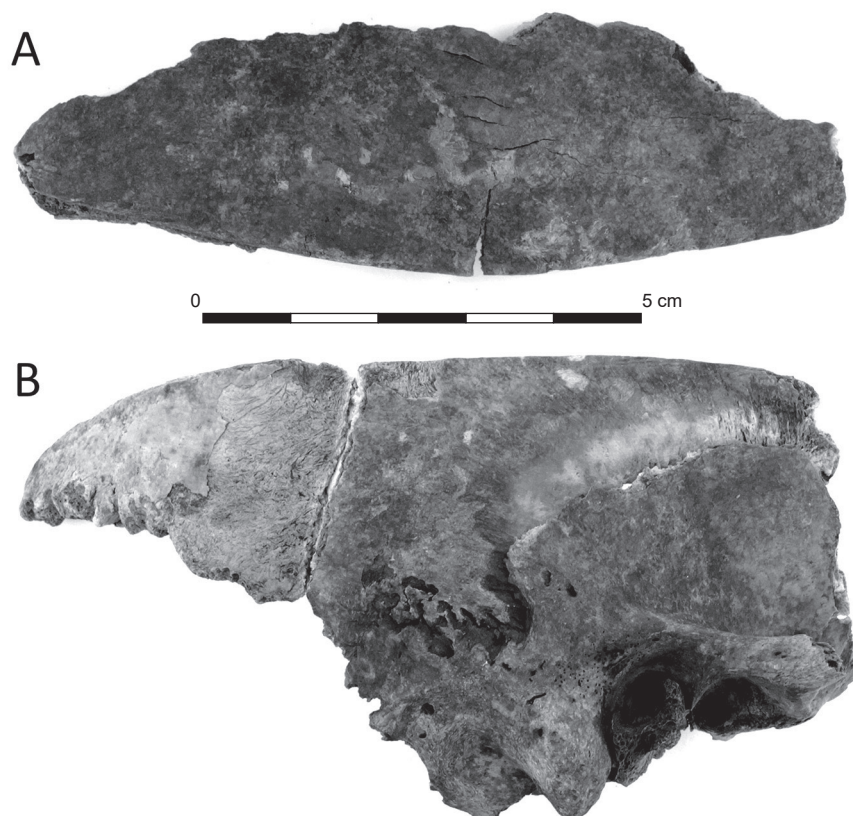
3.4 Artificial interventions on the skull

The available fragments of the skeleton from grave number 841 show both direct and indirect manifestations of pathological processes, some of which appear to be crucial for the reconstruction of our story. On the second lower right molar we can observe an extensive and deep caries in the occlusion surface of the crown. It is the only direct pathological trait recorded on the skeletal and dental remains. The most interesting “find” of our study has been that revealed by the careful observation of several bones of the cranial vault. The most important discoveries relate to the three cranial fragments:

- The first crucial fragment (found as two fragments, then linked together) is made up of part of the right parietal bone (lower back portion with part of *sutura lambdoidea*) loosely connected with the temporal bone (an almost complete squama with a temporal portion of zygomatic arch, an almost complete *processus mastoideus*, tympanic part and petrous part). The parietal and temporal bones are wedged together in a short section of the *sutura parietomastoidea*. The upper edge of this fragment, approximately 12–13 cm long, is sharp and more or less flat and oriented horizontally (Figure 3B).
- The second fragment consists of the upper part of the right parietal bone (without the portion adjacent to the *sutura sagittalis*), whose lower edge (length also approx. 12–13 cm), is also sharp and straight (Figure 3A).
- The third fragment is a part of the frontal bone from the region of the *tuber frontale* (the side is unclear). The upper part does not reach the *sutura coronalis*, whereas the lower edge is sharp and straight (but more abraded than in the case of the parietal bone) and is localized between the *tuber frontale* and supraorbital ridge.

The first and second-mentioned fragments (comprising parts of the parietal and temporal bones) have emerged as a consequence of an incision through the right parietal bone. For this reason, both of these fragments are mutually coherent, but they are not smoothly adjacent because of the pressure and humidity of the earth during the bones' deposition in the ground. The margins of the sharply-cut edges do not show any traces of healing. We can interpret the described incision across the right parietal bone as the

Figure 3. Skeleton number 841: bone fragments showing dissection traces (right parietal and temporal bone). Taken and adapted from Moravcová *et al.* 2015.



remnant of a postmortem intervention into the skull cavity which has resulted in the complete division of the preserved part of the parietal bone. Thus on the right side of the skull, the skull has been cut through at some time after the death of the individual by a section going through the parietal bone from a region approximately 1 cm above the top point of the *sutura squamosa*, towards the region close to the lambda-point (the occipital bone itself was not probably affected by this section).

4. Discussion

In the above text we have outlined the issue of a possible postmortem manipulation of the skeletal remains from grave number 841. The most probable reason for such a type of intervention is the dissection (autopsy) of the head brought about by doubts concerning the death of the individual. Head autopsy, or the opening up of the cranial cavity in order to carry out a pathological inspection of the brain and adjacent structures, usually starts with a cut going around the skull top and the removal of the cranial vault at the level of the parieto-temporal transition. The only part of our skull with very obvious traces of such a procedure is just the right parietal bone, which displays traces of dissection throughout the whole preserved portion. However, because the skull has remained in a fragmentary state of preservation, it is not possible to observe the entire potential course of the dissection; nevertheless, we can reasonably assume that

the dissection initially went across the entire circumference of the cranial vault. As stated above, the third explored fragment pertaining to the frontal bone with an abraded cut edge represents another very probable dissection remnant indicative of a circumcranal incision. Based on these traits, it seems likely that the skull (head) of individual number 841 was subjected to an autopsy intervention.

Based on the aforesaid, we can conclude that the anthropologically examined skeleton number 841 exhumed at St. Luke's cemetery in Moravská Ostrava dates back to the period 1785–1843, belongs to a woman who died aged approximately 20–25 years, and shows traces of an artificially-performed postmortem invasion into the skull cavity. The cemetery in question is relatively recent (Moravec *et al.* 2014), so we can quite reasonably presume that information concerning burials and the background or causes of death of the people buried there would be captured in written sources. Crucially, would we be able to find whatever note reflected the burial of our individual number 841 and see if it contained any information about the possible autopsy? Indeed, we did. By studying the available registers of deaths and similar documents, we were able to obtain important information concerning the deaths and funerals of the citizens of Moravská Ostrava for the first half of the 19th century (Moravcová *et al.* 2015; ACO 1–6). Among other things, we were also able to trace the circumstances of the unclear death of a young girl (woman) named Marianna Máchová, who died in 1837 and was buried at St. Luke's cemetery.

Marianna Máchová was born on 1st July 1817. Her parents were Vincenc Mácha and Veronika Máchová. Marianna's father was born in a honourable family, his ancestors having held important functions in the city council of Moravská Ostrava since the 18th century. Marianna was the second youngest child of 12 siblings, 11 of whom survived to adulthood. While the life of Marianna Máchová was very unexceptional, her death is shrouded in secrecy and doubt. As mentioned in the written sources, Marianna died suddenly on 23rd December 1837, aged 20 years, with shortness of breath (asthma) and a brain stroke. The cause of her death was investigated by a physician who treated her in her last moments. About a week after her death, an important note appeared in the official documents concerning the inheritance procedure – the cause of Marianna's death was specified as suicide (ACO 1). The written sources, however, say nothing more about the circumstances of such a death. Although this is unimportant for our case, based on a more detailed exploration of the archives, it seems that Marianna Máchová succumbed to poisoning by arsenic. Such a form of deadly intoxication is in accordance with the postmortem observations specified in the medical records and with other available information regarding the cause of Marianna's death (Moravcová *et al.* 2015; ACO 1; ACO 2).

The previous "story" suggests that the crucial point of our case is the information that the cause of death of Marianna Máchová was ascertained using cranial dissection. This was carried out no later than 25th December 1837, as mentioned in the archived medical report (ACO 1). One day after this date, Marianna was buried at the cemetery at St. Luke's chapel (ACO 3). The autopsy of Marianna Máchová is the oldest historically-documented intervention of this kind from Moravská Ostrava, meaning that the use of autopsy to uncover the cause of death was uncommon before that time. The next two notified autopsies in Ostrava followed in 1840 – the first related to a 66 year-old man and the second to an 18 year-old youth. Subsequent autopsies were realized in 1847 and later in Ostrava (Moravcová *et al.* 2015, 283; ACO 4–6).

For all the above reasons, we can accept the working hypothesis that the human skeleton in grave number 841 belongs to the remains of Marianna Máchová. First, in accordance with the anthropological outcomes, the skeleton represents the remains of a woman who died in a very young phase of adult life (approximately 20–25 years) and has evidence of some form of artificial cut or dissection intervention into the cranial vault bones. Second, according to the register of deaths, the described grave dates back to the third phase of the cemetery's existence (defined as 1785–1843) during which Marianna died. Third, the archaeological circumstances indicate the heightened expense of the funeral itself, which is also consistent with the archived records regarding the burial costs (ACO 3). However, as previously stated, at least two other historically-documented autopsies were realized during the time of the cemetery's existence at St. Luke's chapel (in 1840) in Moravská Ostrava. Nevertheless, neither of the persons dissected in that year agrees with

the anthropological results of the sex and age assessment of skeleton number 841. The subsequent historical records concerning autopsies in Moravská Ostrava, starting from 1847, relate to a time when the cemetery at St. Luke's chapel no longer served as the primary and predominant place for burial. It was used for only a few years more after the establishment of the new cemetery in Moravská Ostrava, and its burial activities became very sporadic and irregular (Moravec *et al.* 2014, 37).

5. Conclusions

The archaeological excavation in Puchmajerova street in Ostrava, within the area of the former cemetery at St. Luke's chapel, has brought an unusual discovery concerning a connection between some human skeletal remains and the identity of a truly existing person. The most interesting and crucial point of this context consists of the sample of fragments of cranial vault bones belonging to skeleton number 841, showing, in all likelihood, traces of a postmortem dissection. By a process of elimination, based on the results of our archaeological excavation, anthropological findings and archival sources, we can make a preliminary conclusion that the remains of the skeleton in this grave belong to the historically-recorded person named Marianna Máchová (1817–1837), who died by murdering herself (suicide) in unclear circumstances. All the evidence points to the fact that this woman best fits with the anthropological and archaeological observations. The historical records regarding her life and death (including information about the head autopsy) can be considered as important additional proof of a correct interpretation of the cut-like traces found on the skull.

References

- ACO 1: Archive of the city of Ostrava, register of city of Moravian Ostrava, old registry, cart. No. 287, catalogue No. 4329.
- ACO 2: Archive of the city of Ostrava, register of city of Moravian Ostrava, old registry, cart. No. 170, catalogue No. 1410.
- ACO 3: Archive of the city of Ostrava, register of parish office of Moravian Ostrava, accession number 180, Book of parish fees 1838–1851.
- ACO 4: Archive of the city of Ostrava, files of city of Moravian Ostrava, old registry, cart. No. 292, catalogue No. 4521 and 4524.
- ACO 5: Archive of the city of Ostrava, files of city of Moravian Ostrava, old registry, cart. No. 210, catalogue No. 1925.
- ACO 6: Archive of the city of Ostrava, files of city of Moravian Ostrava, old registry, cart. No. 229, catalogue No. 2736.
- ACSÁDI, G., NEMESKÉRI, J. 1970: *History of human life span and mortality*. Akadémiai Kiadó, Budapest.
- BACH, H. 1965: Zur Berechnung der Körperhöhe aus den langen Gliedmassenknöcheln weiblicher Skelete. *Anthropologischer Anzeiger* 29, 12–21.
- BRŮŽEK, J. 2008: Současná česká paleodemografie: falešné naděje přílišného optimismu a nový reálný cíl. *Archeologické rozhledy* 60, 329–344.
- BUIKSTRA, J. E., UBELAKER, D. 1994: *Standards for Data Collection from Human Skeletal Remains*. Missouri Archaeological Society. Proceedings of a Seminar at the Field Museum of Natural History.

- Arkansas Archaeological Survey Research Seminar Series 44. Arkansas.
- ČERNÝ, M. 1971: Určování pohlaví podle postkranialního skeletu. In: Vlček, E. (Ed.): *Symposium o určování stáří a pohlaví jedince na základě studia kostry*. Národní muzeum, Praha, 46–62.
- ČERNÝ, M., KOMENDA, S. 1980: Sexual Diagnosis by the Measurements of Humerus and Femur. *Sborník prací Pedagogické fakulty UP Olomouc-Biologie* 2, 147–167.
- ČERNÝ, M., KOMENDA, S. 1982: Reconstruction of body height based on humerus and femur lengths (material from Czech lands). In: *2nd Anthropological Congress of Aleš Hrdlička*. Charles University, Prague, 475–479.
- KRÁLÍKOVÁ, M. 2007: Devocionálie z brněnského hřbitova 18.–19. století jako součást katolického pohřebního ritu. *Brno v minulosti a dnes* 20, 111–121.
- KROGMAN, W. M., ISCAN, M. Y. 1986: *The Human Skeleton in Forensic Medicine*. Charles C Thomas Publisher, Springfield, Illinois, USA.
- LINC, R. 1971: *Kapitoly z růstové a funkční morfologie*. Univerzita Karlova v Praze FTVS, SPN, Praha, 112–117.
- LOVEJOY, C. O. 1985: Dental Wear in Libben Population: Its Pattern and Role in the Determination of Adult Skeletal Age at Death. *American Journal of Physical Anthropology* 68/1, 47–56.
- MARTIN, R., SALLER, K. 1957: *Lehrbuch der Anthropologie*. G. Fischer Verlag, Stuttgart.
- MEINDL, R. S., LOVEJOY C. O. 1985: Ectocranial suture closure. A revised method for the determination of skeletal age at death based on the lateral-anterior sutures. *American Journal of Physical Anthropology* 68/1, 57–66.
- MORAVCOVÁ, I., MORAVEC, Z., NOVOTNÁ, J., ŽIVNÝ, M. 2015: Mariana Máchová (1817–1837) a její rodinné zázemí. In: Przybylová, B. et al. (Ed.): *Ostrava 29. Příspěvky k dějinám a současnosti Ostravy a Ostravska*. Ostrava, 272–292.
- MORAVEC, Z., MORAVCOVÁ, I., ŽIVNÝ, M., ZEDNÍKOVÁ MALÁ, P. 2014: *Příběh zapomenutého hřbitova*. Ostravské muzeum, Ostrava.
- PIONTEK, J., WEBER, A. 1990: Controversy in paleodemography. *International Journal of Anthropology* 5, 71–83.
- RUBINKOVÁ, M. 1999: Pohřební ritus 17. a 18. století na Moravě. MS. Master diploma thesis. Deposited: Library of Institute of Anthropology, Faculty of Science, Masaryk university, Brno.
- SCHWARTZ, J. H. 1995: *Skeleton keys*. Oxford University Press, New York, Oxford.
- SJØVOLD, T. 1990: Estimation of Stature from Long Bones Utilising the Line of Organic Correlation. *Human Evolution* 5, 431–447.
- STEWART, T. D. 1979: *Essentials of Forensic Anthropology*. Charles C Thomas Publisher, Springfield, Illinois, USA.
- STLOUKAL, M. et al. 1999: *Antropologie. Příručka pro studium kostry*. Praha.
- UNGER, J. 2006: Pohřební ritus 1. až 20. století v Evropě z antropologicko-archeologické perspektivy. In: Malina, J. (Ed.): *Panoráma biologické a sociokulturní antropologie* 25, Cerm – Nauma, Brno.
- VIGNEROVÁ, J., BLÁHA, P. 1998: The growth of the Czech child during the past 40 years. In: Bodzsár, É. B., Susanne, C. (Eds.): *Secular growth changes in Europe*. Eötvös University Press, Budapest, 94–107.
- VIGNEROVÁ, J., RIEDLOVÁ, J., BLÁHA, P., KOBZOVÁ, J., KREJČOVSKÝ, L., BRABEC, M., HRUŠKOVÁ, M. 2006: *6. celostátní antropologický výzkum dětí a mládeže 2001, Česká republika. Souhrnné výsledky. 6th Nation-wide Anthropological Survey of Children and Adolescents 2001 Czech Republic. Summary results*. First ed. Charles University, State Health Institute, Praha.
- ŽIVNÝ, M., MORAVEC, Z., UHROVÁ, V. 2011: Hřbitov okolo kaple sv. Lukáše v Ostravě – archeologicko-antropologická analýza. *Časopis Slezského zemského muzea, series B* 60, 113–126.

