



INTERDISCIPLINARIA ARCHAEOLOGICA

NATURAL SCIENCES IN ARCHAEOLOGY

homepage: <http://www.iansa.eu>



Short Contribution: Severe Enamel Defects and Malformations of Canines in Pre-Historic and Historic Domestic Pigs from Bohemia

Wolf-Rüdiger Teegen^a, René Kysely^{b*}

^aInstitut für Vor- und Frühgeschichtliche Archäologie und Provinzialrömische Archäologie & ArchaeoBioCenter, Ludwig-Maximilians-Universität, Geschwister-Scholl-Platz 1, 80539 München, Germany

^bInstitute of Archaeology of the Academy of Sciences of the Czech Republic, Prague, v. v. i., Letenská 4, 118 00, Prague, Czech Republic

ARTICLE INFO

Article history:

Received: 7. November 2014

Accepted: 23. December 2014

Keywords:

domestic pig (*Sus scrofa* f. *domestica*)

enamel defect

enamel and root hypoplasia

Iron Age (La Tène period)

Middle Ages

ABSTRACT

In this paper four cases of severe enamel and dentine defects in the upper canines of male domestic pigs (*Sus scrofa* f. *domestica*) from the Iron Age and medieval sites in Bohemia (Czech Republic) are presented. Such severe defects observed in the osteoarchaeological record are a fairly rare condition. They are in all likelihood the result of intra and extra alveolar traumas. In two cases the growing area was completely or partially divided, probably due to a traumatic incidence. The origin of the traumatic insults could be intra- or inter-species fights, search for food or other accidents. Human maltreatment could also not be excluded. A twisted canine was observed in one case. A description of an anomaly on one lower female pig canine is also included.

1. Introduction

Pig teeth are a grateful object for studying malformations as well as enamel or dentine defects in veterinary anatomy and pathology as well as in osteoarchaeology. This field of study has been more or less neglected, however, in osteoarchaeology and paleopathology. Nevertheless, there are classic observations on more recent finds which Frank Colyer collected in the first decades of the 20th century (Colyer 1936). Fortunately, an updated edition of his book was published by A. E. W. Miles and Caroline Grigson in 1990. Only since the turn of the Millennium, has interested turned toward enamel defects of pig teeth, dealing mostly, however, with premolars and molars (e.g. Dobney, Eryvnyck 1998; 2000; 2002; Teegen, Wussow 2000; Teegen 2005; 2006; 2013; Magnell, Carter 2007; Pigièrè 2009).

The canines of the male pig – either of the wild (*Sus scrofa*) or the domestic form (*Sus scrofa* f. *domestica*) – are of particular interest. These canines are continuously

growing (elodont) and are rootless (aradicular hypsodont). They therefore continue growing until the individual dies. The elodont canines have an extended pulp with a rich blood supply. There are enough cells in this and the adjacent areas continually reproducing themselves. There is consequently a constant stream of cells present, ready to heal damaged tissue in the canine area (Miles, Grigson 1990, 404). This means that the dentine cells of the canines of male pigs have a high repair potential. This is quite different with the female pigs (Figure 6) where the canines are not continuously growing.

For the wild boar, tusk anomalies – mainly of the lower canines – are sometimes described in veterinary or wildlife literature (e.g. Palášthy, Palášthy 1991; Kierdorf, Rùhe 2002; Kierdorf, Kierdorf 2003; Kierdorf *et al.* 2004; Konjević *et al.* 2004; 2006). This is due to the fact that (mainly the lower) tusks are valuable trophies for hunters. Alterations of the maxillary canines are reported less (e.g. Konjević *et al.* 2004).

Alterations of the canines of male domestic pigs have gained much less attention than wild boars. This is the case both for recent as well as archaeological specimens. This is also valid for enamel hypoplasia which can often be observed

*Corresponding author. E-mail: kysely@arup.cas.cz

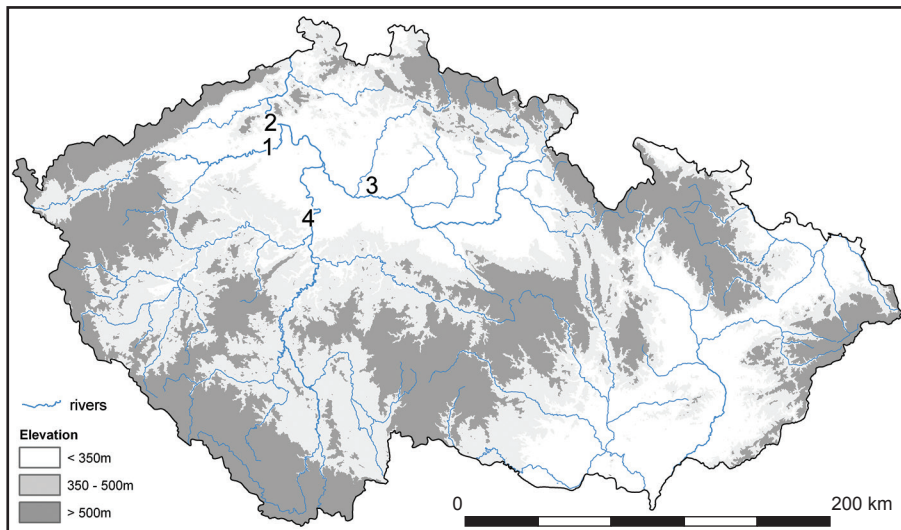


Figure 1. Map of the Czech Republic with the sites: 1 – Radovesice, 2 – Lovosice, 3 – Stará Boleslav, 4 – Praha (Prague). Map by R. Kyselý.

in canines (*cf.* Teegen 2013, 60–61), as they continue to receive less attention than molars or premolars.

The average growth rates (in mm/month) for pig canines are also not all that well known. An average monthly growth of approx. 2 mm can be assumed for wild boars above 20 months of age from the southern Ukraine (Woloch 2002,

188, Figure 2). It could be similar or less, probably between 1 mm and 2 mm/month, for domestic pigs.

Despite modifications on bovine incisors having been recently described by Kyselý (2007; 2009; 2012) and certain other dental deformations from the Czech territory having been mentioned occasionally, there is no paper specialised

Table 1. Overview of the analysed finds. Measurements in mm. Abbreviations: GE = growing end (\approx EDJ = Enamel-Dentine-Junction), ED = enamel defect.

Site	1: Radovesice	2: Lovosice – Resslerva ulice	3a: Stará Boleslav	3b: Stará Boleslav	4: Prague – Vojanovy sady
Site specification	Radovesice 23, Lukovský potok, feat. 107/72	trench 2, feat. 8, layer 0–10 cm	trench LXX, square 102, layer 21225	trench XVIII, layer 6367	layer A
Settlement description	early La Tène (A-B1) settlement	middle La Tène (C) settlement	medieval stronghold (bailey)	medieval stronghold (moat)	medieval town
Archaeological dating	5 th –beginning of the 4 th cent. BC	3 rd –2 nd cent. BC	end of the 9 th – turn of 13 th cent. AD	end of the 9 th – turn of 12 th cent. AD	2 nd half of the 13 th cent. AD
Taxonomic status	domestic	domestic	domestic	domestic	domestic
Tooth	left upper canine	right upper canine in its alveolus	left upper canine	left lower canine	right upper canine
Sex	male	male	male	female	male
Age at death	adult (> 18 months)	adult (approx. 18–24 months)	adult (older?) (> 18 months)	adult	subadult/adult (> 15 months)
Length	41.6	44.2		61.8	38.6
Length (outer arch)	52.0			89.0	41.0
Length (inner arch)	41.0			68.0	35.0
Minimum diameter at GE	8.3	12.2		10.9	10.9
Maximum diameter at EDJ	14.4	16.3		14.3	18.0
Height of ED above GE	31.7	not determined	not determined		19.0–14.1
Breadth of the defect	13.2			3.2 × 4.7 × 1.0	
Figure	2	3–4	5	6	7

Table 2. Lovosice – Resslerva ulice (nr. 2). Measurements (in mm) of the maxilla. Values in brackets = approximate.

M1-M3	P1-M3	P1-P4	P2-M3	P2-P4	Length of M3	Breadth of M3	Max. diameter of canine alveolus
(60.9)	(100.8)	40.2	(93.8)	33.3	30.7	17.3	21.7

on animal tooth pathologies in Czech archaeozoological literature. The presented report can therefore be considered a pilot case.

2. Materials and Methods

In this short contribution we would like to present five cases of enamel defects on pig canines originating from archaeological contexts in Bohemia (Czech Republic; Figure 1). Each case originates from the La Tène sites Radovesice and Lovosice – Resslova ulice. The other ones are Medieval and come from Prague – Vojanovy sady and from Stará Boleslav.

All the finds were dated by co-found artefacts (mainly pottery) with the help of the evidence of the stratigraphic situation (see the cited archaeological literature); radiocarbon dating was not directly applied. It is well known that stratigraphic contaminations can play a role in poly-cultural archaeological situations. The evidence indicates that it is not an issue in our cases. Despite certain older settlement layers (11th to the first half of the 13th century) having been detected in the stratigraphical set at Prague – Vojanovy sady, layer “A” only represents refuse from the second half of the 13th century, therefore contamination is not all that probable. Other finds described here are more reliable and narrowly dated (Table 1).

Sex was determined using the morphology of the canines. The age determination of pig canines is only quite approximative (Habermehl 1975). For wild boars the length of the whetting surface can be an age indicator (Wagenknecht 1979; Habermehl 1985).

The definitions of the measurements follow von den Driesch (1976). The main reference point for all of the other

measurements is the Enamel-Dentine-Junction (EDJ). In the canines of males there is only a small seam of dentine without enamel, generally less than 5–10 mm.

The pathological changes in the maxillary canines were classified according to Palásthy and Palásthy (1991), Teegen (2004), Konjević *et al.* (2004) and Konjević (2006).

3. Results

The canines belong – with one exception – to male domestic pigs. In four out of five cases the canines of the upper jaws are present (Table 1). In one case (nr. 3b), the lower canine of a female domestic pig is present. All the individuals were at least 15 months old (Table 1).

Description of the finds (sorted in chronological order):

Site 1: Radovesice (distr. Litoměřice):

The canine discussed here (Table 1; Figure 2) was found in feature 107/72 of the Iron Age village Radovesice 23, Lukovský potok, distr. Litoměřice (Bohemia). The excavation in 1972 was led by J. Waldhauser. The archaeological description was published by Waldhauser (1993), the archaeozoological report was published by Peške (1993). The feature belongs to the settlement horizon II–III (IIB) which is dated to La Tène A-B1 (5th – beginning of 4th century BC).

The left upper canine of an adult male domestic pig (>18 months) is completely preserved (Figure 2). The tip is abraded or broken. The complete tooth crown is torn at approx. 20°. The enamel layer is only partially present.

The enamel formation at the tip of the canine is regular. A deep sulcus with a width of about 4 mm is approximately

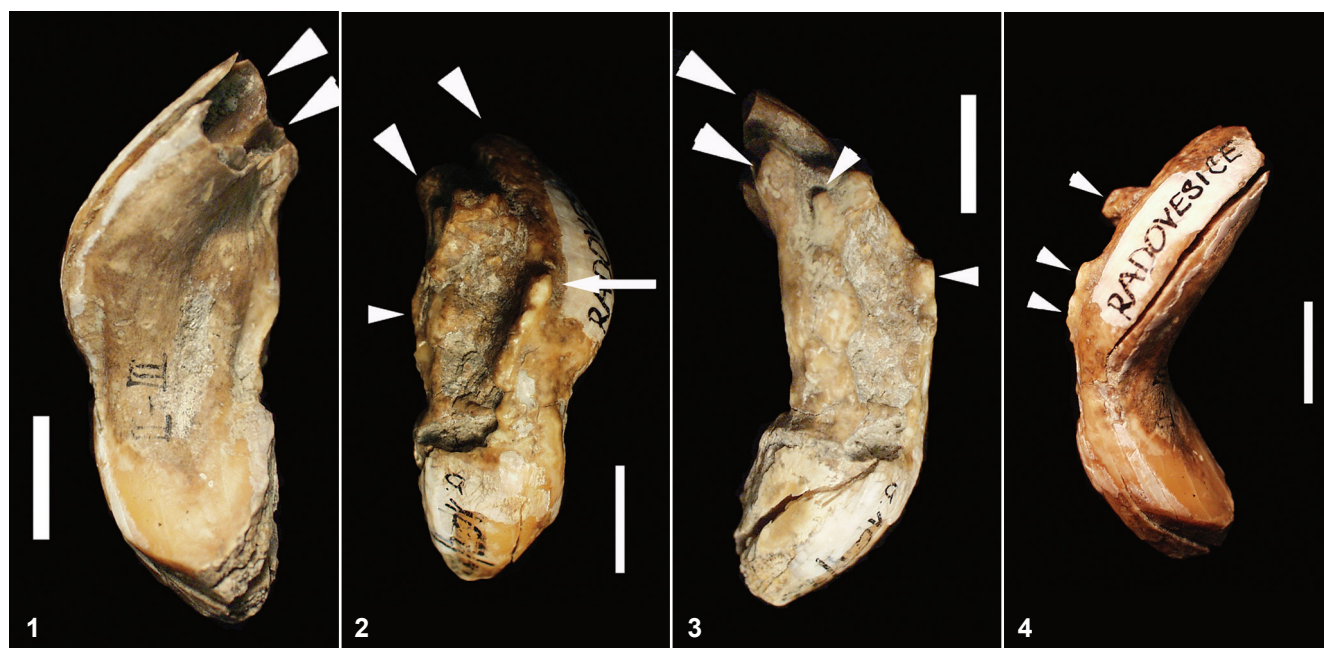


Figure 2. Radovesice (Bohemia), male domestic pig, left upper canine (see Table 1 for details). 1 – Buccal view. 2 – Disto-palatinal view. 3 Distal view. 4 – Mesio-palatinal view. Large arrow heads: separated growing areas, small arrow heads: exostoses, arrow: the distal rims of the defect are clearly marked and are forming ridges. Scale = 1 cm. Photo: W.-R. Teegen.

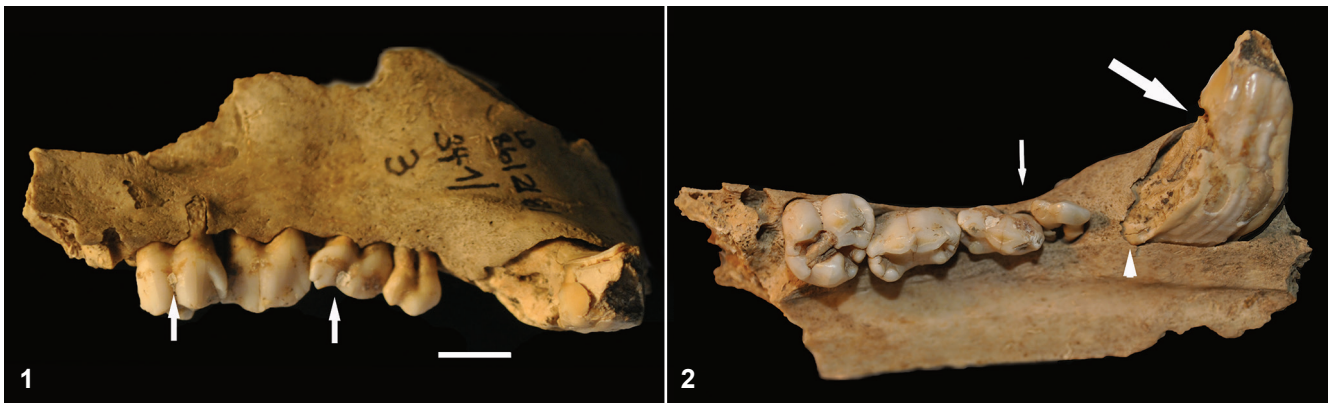

Figure 3. Lovosice – Resslerva ulice (Bohemia), male domestic pig, right maxilla with crowding of the pre-molars P1-4 and enamel and dentine defects of the right upper canine (see Table 1 and 2 for details). 1 – Lateral view. The arrows indicate deposits of white dental calculus. The dehiscence of the alveolar rim at the eroded mesio-buccal root and fenestration of the disto-buccal root of P4. 2 – Occlusal view is visible. Large arrow: fracture line, arrow head: new dentine formation, small arrow: crowding. Scale = 1 cm. Photo: R. Kysely/W.-R. Teege.

31.7 mm (linear distance) resp. 35.0 mm (curvature) above the Enamel-Dentine-Junction (EDJ) (Figure 2). This sulcus is present on the mesial, palatal and distal side of the canine. Only the buccal part shows little alterations. It is clearly visible here, however, that the crown of this canine is torn (Figure 2.1). If we assume a monthly growth rate of 1–2 mm, than the defect developed between 17 and 35 months prior to death.

The disto-palatinal area of the canine reveals a quite abnormal surface. There are holes and the enamel layer is mostly missing. This defect has an extension of approx. 13.2×31.7 (linear distance) resp. 35.0 mm (curvature). The mesial and distal rims of the defect are clearly marked and form ridges. These defect walls contain several bubble formed structures of a lighter colour. They in all likelihood consist of enamel pearls. One rim measures 2.2×14.0 mm with a height of approx. 2 mm. The defect itself is without enamel. It only consists of dentine which shows three larger holes with an irregular surface (Figure 2). The opposite rim is more irregular; the basal is an irregular exostotic formation of $3.9 \times 6.0 \times 4.0$ mm dentine extension. It is located 5 mm above the EDJ. The enamel layer runs in the regular area to the end of the tooth to the EDJ.

Of particular interest is the fact that there are two separate growing ends of the upper canine (Figures 2.1 and 2.2, large arrow heads).

Site 2: Lovosice – Resslerva ulice (distr. Litoměřice):

The excavation of 1986 was directed by V. Salač and partly published in 1990 (Salač 1990). The left maxillary fragment with the canine of a male domestic pig (inv. no. 86/2/8/341/3) was found in the middle La Tène settlement phase in trench 2, feature 8, 0–10 cm below the top of the feature (Table 1). It dates to the 3rd–2nd century BC. The archaeozoological material was studied by R. Kysely (2001) and is still unpublished.

The pathologically altered canine was still in its alveolus in a fragment of the left maxilla (Figure 3.1). The premolars 1–4 and molars 2 and 3 are also present. Their degree of abrasion is low (premolars visible on Figure 3.2). It belongs

to an adult individual of approx. 20–26 months of age¹. The metric data can be found in Table 2.

There is a defect running perpendicular to the axis on the distal part of the canine. It is located approx. 10 mm from the top of the crown (Figure 4.1). Below this defect a furrow begins which runs to the growing end. There is also an area of about 10.2×19.9 mm distally which shows irregular dentine and enamel formation. Below the defect on the distal side there are also irregularities in the enamel formation on the palatal part of the canine (Figure 4.2).

The growing end is partially compressed and exhibits distally a deep longitudinal furrow which nearly separates it (Figure 4.1). There is some new dentine formation inside the growing end, attached to the furrow (Figure 4.1).

¹Molar 2 has dentine abraded (cf. Grant's 1982 stage "e–f"); molar 3 only has enamel abraded (Grant's 1982 stage "a").



Figure 4. Lovosice – Resslerva ulice (Bohemia), male domestic pig, right upper canine with enamel defects. 1 – Disto-buccal view. 2 – Palatal view. Scale = 1 cm. Photo: R. Kysely.

There is a wedge-like defect on both palatinal roots of premolar 1 below the EDJ (Figure 3.2). A small deposit of white coloured dental calculus is present on the 2nd and 4th upper right premolars (Figure 3.1 – arrows). There is also a crowding of the left upper premolars P1-4.

The described case is a single strong pathology observed among 39 male upper canines existing in the assemblage from Lovosice – Resslova ulice.

Site 3: Stará Boleslav (distr. Prague – východ):

The excavation of the former medieval stronghold in 1996 was directed by I. Boháčová and published in 2003 (Boháčová 2003). The mammal bones analysis was published by Kysely (2003). Two samples (Table 1) from this site are presented here.

Case 3a: The maxillary canine of a male domestic pig (inv. no. 5617) was found in the bailey of the stronghold (trench LXX, square 102, layer 21225) and is dated between the end of the 9th and the turn of the 13th cent. The canine shows a well healed fracture with some new formation of dentine on the buccal aspect (Figure 5.1). There is also some new dentine formation of the palatinal side (Figure 5.2, medium arrow head). During the growth of the canine at least two linear enamel hypoplasias developed (Figure 5, small arrow heads). Their distance is approximately 6.5 mm. This means they could probably have developed after an interval between 3 and 6 months. The described case is a single strong pathology observed among 38 male upper canines existing in the assemblage from Stará Boleslav.

Case 3b: The lower left canine of an adult female pig (inv. no. 2946, Figure 6) comes from a moat at the stronghold (from layer 6367, trench XVIII) and is dated between the end of the 9th and the turn of the 13th cent. There is a spherical formation with the dimensions of $3.2 \times 4.7 \times 1.0$ mm at approximately the EDJ. It is covered with tooth cementum. It could consequently not be clearly determined whether it is “enamel pearl” or a malformation of dentine (“dentine

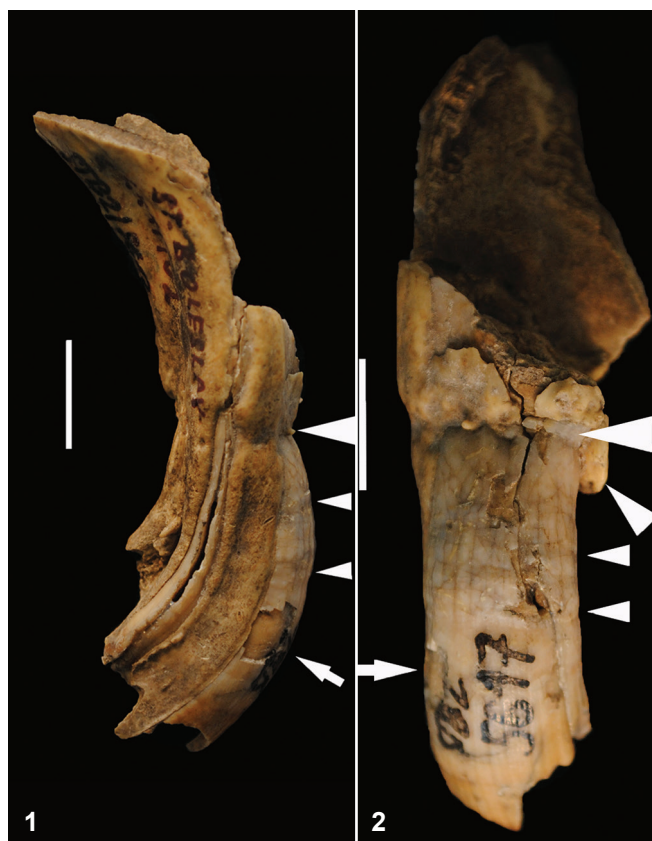

Figure 5. Stará Boleslav (Bohemia), male domestic pig, left upper canine of a subadult individual, well-healed fracture, dentine repair, enamel hypoplasias (see Table 1 for details). 1 – Distal view. 2 – Palatinal view. Large arrow head: fracture line, medium arrow head: new dentine formation, small arrow heads: enamel hypoplasia, arrow: pseudo-pathology (missing enamel). Scale = 1 cm. Photo: R. Kysely/W.-R. Teegen.

pearl”). It probably developed around the end of the crown formation. This abnormality was observed among 42 female lower canines existing in the assemblage from Stará Boleslav.

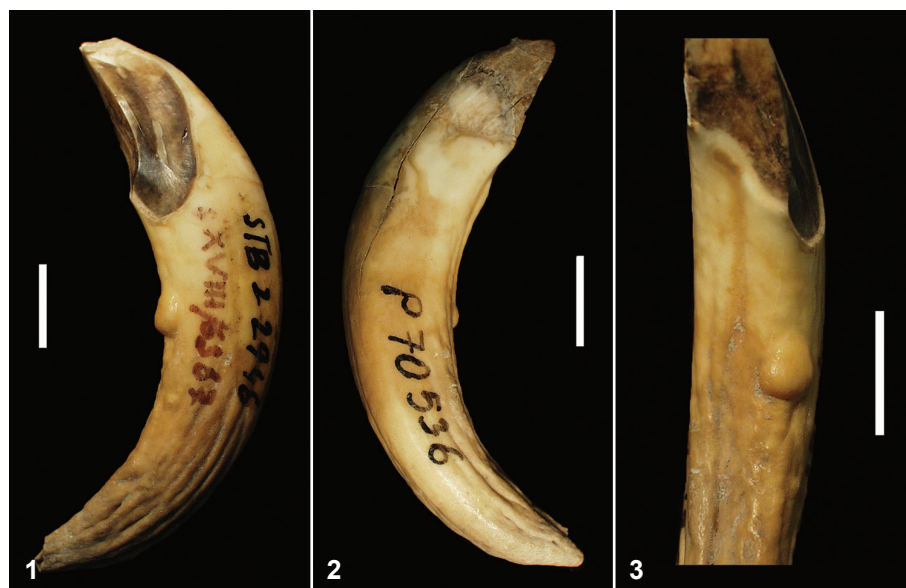


Figure 6. Stará Boleslav (Bohemia), female domestic pig, left lower canine of an adult individual with a dentine (?) pearl on the root near the dento-enamel junction (see Table 1 for details). 1 – Lateral view. 2 – Lingual view. 3 – Close-up. Scale = 1 cm. Photo: W.-R. Teegen.

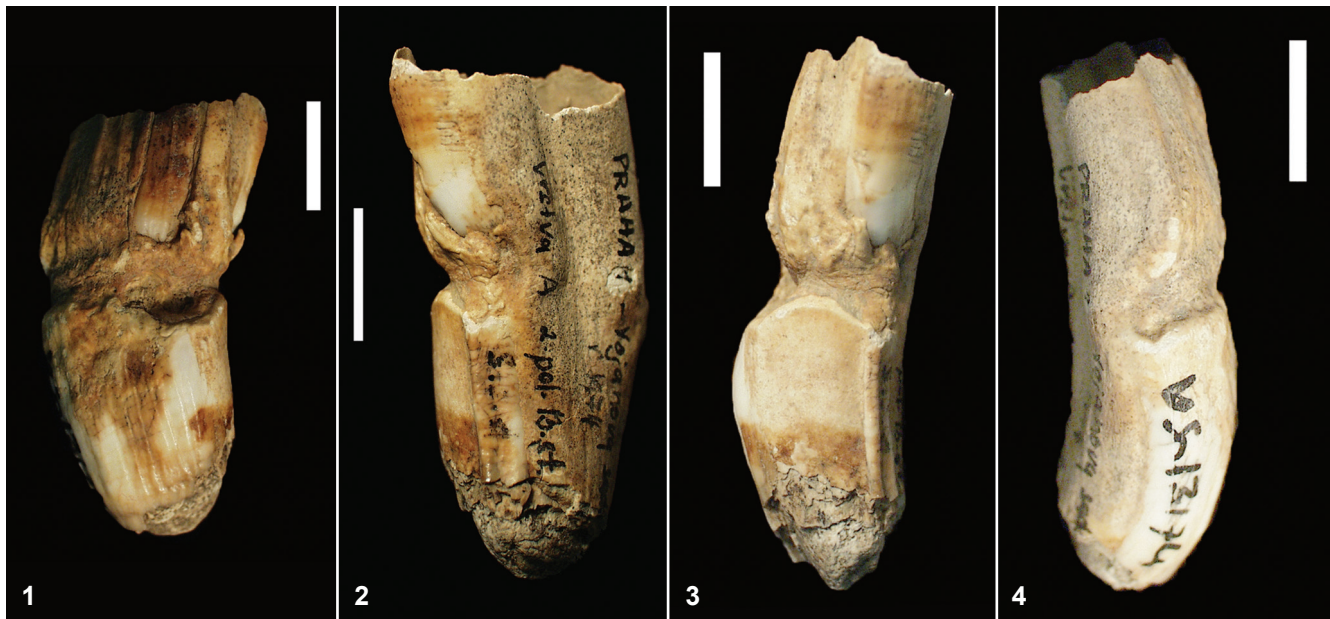

Figure 7. Prague – Vojanovy sady (Bohemia), male domestic pig, right upper canine with an enamel and a dentine defect (see Table 1 for details). 1 – Buccal view. 2 – Bucco-distal view. 3 – Disto-buccal view. 4 – Palatinal view. Scale = 1 cm. Photo: W.-R. Teegen.

Site 4: Prague – Vojanovy sady (distr. Prague):

The excavation of 1974 was directed by L. Hrdlička (Hrdlička 1977; 1991). The canine (inv. no. VS-13/74) was found in layer A, consisting of refuse outside the wall, and is dated to the second half of the 13th cent. The archaeozoological material was studied by L. Peške (1976), but has remained unpublished.

The right upper canine of an adult male domestic pig is completely preserved (Table 1, Figure 7). Its tip is broken/abraded, the enamel is well developed, showing small ridges in the longitudinal direction. There is a deep sulcus, running from the mesial via the palatinal to the distal part of the canine, at a height of approximately 14.1–19.0 mm above the growing end of the canine. The maximal breadth of the sulcus is 5.4 mm. It is approximately 0.8 mm deep on both sides, 1.7 mm in all. The superior margin of the sulcus is the fracture line. A fairly massive dentine formation is located between the enamel in the sulcus (Figure 7.1). There is a layer of repaired dentine on the inferior margin of the enamel defect (Figure 7). At least one exostotic new dentine formation is present (Figure 7.3).

4. Discussion

Four out of the five canines (nr. 1, 2, 3a and 4) presented here show severe enamel and dental defects (Figures 2, 3, 4, 5, 7). All these four canines demonstrate a wedge-like defect on their palatinal surface, approximately at the height of the alveolar margin. Furthermore, the canine nr. 1 from Radovesice shows an angular form (Figure 2.4).

The severe enamel defect is the most important observed feature. It should be noted that all the canines manifest quite

a normal enamel formation inferior and superior of the defect. The defect itself is located on the mesial, palatinal and distal side and results in a deep and wide sulcus and a wedge-like structure.

Wedge-like defects are quite typical for intravital fractures (cf. Miles, Grigson 1990, 404–405, Figure 19.15; Palášthy, Palášthy 1991, 195–198; Konjević *et al.* 2006, Figure 3). We can therefore conclude that in our cases the enamel defects had a traumatic origin. Canine fractures are not unusual in wild or domestic pigs, in particular males. The canine protrudes from the mouth cavity. It can consequently be easily affected by external forces. These can be the results of intra- or inter-species fights or other accidents, e.g. during food search (Konjević *et al.* 2006, S93 with ref.) or in a barn. Amongst domestic pigs, maltreatment can also not be excluded.

Several features should be discussed beginning with the tip of the crown. All the maxillary canines presented here reveal a splintered tip. The colour and nature of the tips indicate an ancient origin (and not recent causation, e.g. during excavation). This alteration could be caused by injuring the canine perimortally.

Canine nr. 1 from Radovesice only shows a more or less normal surface formation on the buccal and mesial facies. No enamel is present at the disto-palatinal side. The surface is also quite irregular and cavernous (Figure 2). The enamel formation stopped here completely. There is only irregular enamel formation in the form of enamel pearls at the margins of the defect (Figure 2).

The layer of dentine which covers the inferior enamel margin of the defect on canine nr. 4 from Prague – Vojanovy sady (Figure 7) is a good indicator of the presence of a fracture. A stratigraphy is present here where the secondary or

tertiary repair dentine covers the enamel. It is not quite clear whether the defect was localized in the alveolus or above the alveolar rim. A very slight exostotic dentine formation, which runs over the enamel, is also present in canine nr. 3a from Stará Boleslav (Figure 5.2).

The disto-palatinal part of the right upper canine nr. 2 from Lovosice – Resslova ulice is surrounded from the alveolar rim (see Figure 3.2, arrow). This fits nicely and is an indication that this new formed dentine and enamel developed inside the alveolus. It seems likely that the defect on the distal side below the tip developed intra-alveolar, which is interesting if we consider a traumatic causation.

Two canines exhibit changes in the growing ends. The growing end of the left upper canine from Radovesice is separated (Figure 2.1 and 2.2). There are consequently two growing ends present. They resemble a similar case in a recent wild boar from Croatia (Konjević *et al.* 2004, 405, Figure 2), in which case, an intra-alveolar infraction was probably the cause. As mentioned above, a traumatic origin for the defect also seems quite probable in our case. The second canine comes from Lovosice – Resslova ulice. Here a deep furrow is present which nearly separates the growing end (Figure 4.1). As described above, the furrow is probably the result of a traumatic impact on the growing canine.

The canine from Radovesice is somewhat twisted (Figure 2). A recent tusk of a wild boar from Slovakia also exhibits a twist (Konjević *et al.* 2006, S95, Figure 1.A). Twisting can be the result of duplication (Konjević *et al.* 2006, S96, Figure 4) when one canine grows against the other one. Twisting occurs not only in boars but also in other tusk bearing animals such as elephants (Miles, Grigson 1990).

The defects shown here are severe enamel defects but not severe enamel hypoplasias. The only enamel hypoplastic defects can be seen on Figure 5 (small arrow heads), depicting the canine from Stará Boleslav. Here at least two hypoplasias on the palatinal side are present.

Enamel hypoplasias on the canines can often be observed in wild and domestic pigs. They are, however, less studied in the paleopathological literature. It can be sometimes difficult to distinguish between normal enamel formation and slight hypoplasias.

5. Conclusion

Enamel defects such as hypoplasias on the canines of male pigs – either domestic or wild – are an extremely interesting phenomenon from a biological point of view. Due to the continuous growth of male canines until its bearer's death, the canines are an “archive of the life history” of a particular individual. The lower and upper canines document growth disruptions during the major part of the adult life. This is quite unique for domestic mammals. Although there are several papers dealing with enamel defects on recent boars tusks (e.g. Palášthy, Palášthy 1991; Kierdorf, Kierdorf 2003; Kierdorf *et al.* 2004; Konjević *et al.* 2006), no author has discussed the time of onset of these defects. The same is true

for prehistoric and historic finds of canines of domestic pigs. This precious body of information is still rarely discussed in paleopathological literature (*cf.* Teegen 2013, 60–61). Further studies are required for an assessment of the accurate monthly developing rate of canines in male domestic (and wild) pigs.

Acknowledgements

This study was made possible by an exchange programme of academic teachers between Charles University in Prague and Ludwig-Maximilians-University in Munich. One of the authors (WRT) is grateful to the committee who made this visit possible and in particular to Prof. Dr. Jan Klápště, Chair of the Department of Archaeology of the Faculty of Arts, for his invitation and to Doc. Dr. Vladimír Salač who made the contacts at the Institute of Archaeology of the Academy of Sciences of the Czech Republic. We would also like to thank V. Salač for information on the dating of the find from Lovosice – Resslova ulice. This study was supported in part from RVO: 67985912 (RK).

References

- BOHÁČOVÁ, I. (Ed.) 2003: *Stará Boleslav. Přemyslovský hrad v raném středověku. – Stará Boleslav. Přemyslid Stronghold in the early Middle Ages.* Mediaevalia archaeologica 5. Prague.
- COLYER, F. 1936: *Variations and Diseases of the Teeth of Animals.* John Bale, Sons & Danielsson, London.
- DOBNEY, K., ERVYNCK, A. 1998: A protocol for recording linear enamel hypoplasia on archaeological pig teeth. *International Journal of Osteoarchaeology* 8, 263–273.
- DOBNEY, K., ERVYNCK, A. 2000: Interpreting Developmental Stress in Archaeological Pigs: the Chronology of Linear Enamel Hypoplasia. *Journal of Archaeological Science* 27, 597–607.
- DOBNEY, K., ERVYNCK, A., LA FERLA, B. 2002: Assessment and Further Development of the Recording and Interpretation of Linear Enamel Hypoplasia in Archaeological Pig Populations. *Environmental Archaeology* 7, 35–46.
- VON DEN DRIESCH, A. 1976: *A guide to the measurement of animal bones from archaeological sites.* Peabody Museum Bulletin 1. Harvard University, Cambridge, Mass.
- GRANT, A. 1982: The use of tooth wear as a guide to the age of domestic ungulates. In: Wilson, B., Grigson, C., Payne, S. (Eds.): *Ageing and Sexing Animal Bones from Archaeological sites.* British Archaeological Reports, British Series 109. BAR, Oxford, 91–108.
- HABERMEHL, K.-H. 1975: *Altersbestimmung bei Haus- und Labortieren.* Second ed. Parey, Hamburg, Berlin.
- HABERMEHL, K.-H. 1985: *Altersbestimmung bei Wild- und Pelztieren. Möglichkeiten und Methoden.* Second ed. Parey, Hamburg, Berlin.
- HRDLÍČKA, L. 1977: Praha 1 – Malá Strana, terasa ve Vojanových sadech, ppč. 148. *Výzkumy v Čechách* 1974. 159–160.
- HRDLÍČKA, L. 1991: Praha 1 – Malá Strana, Vojanovy sady ppč. 148. NZ o zjišťovacím výzkumu v r. 1974. Unpublished report TP-1991-4284. Deposited: Archiv of Institute of Archaeology of the Academy of Sciences of the Czech Republic, Prague.
- KIERDORF, H., KIERDORF, U. 2003: Abnormal lower tusks in a male wild boar (*Sus scrofa* L.). *Zeitschrift für Jagdwissenschaft* 49(2), 150–155.
- KIERDORF, H., RÜHE, F. 2002: Tetracyclinmarken an den permanenten Eckzähnen von Wildschwein-Keilern (*Sus scrofa* L.). *Zeitschrift für Jagdwissenschaft* 48, 114–118.

- KIERDORF, U., KONJEVIĆ, D., JANICKI, Z., SLAVICA, A., KEROS, T., ČURLIK, J. 2004: Tusk abnormalities in wild boar (*Sus scrofa* L.). *European Journal of Wildlife Research* 50(1), 48–52.
- KONJEVIĆ, D., KIERDORF, U., VERSTRAETE, F. J. M., JANICKI, Z., SLAVICA, A., KEROS, T., SEVERIN, K. 2004: Malformation of the permanent maxillary canine after dental infraction in a wild boar (*Sus scrofa* L.). *Journal of Zoo and Wildlife Medicine* 35(3), 403–405.
- KONJEVIĆ, D., KIERDORF, U., MANOJLOVIĆ, L., SEVERIN, K., JANICKI, Z., SLAVICA, A., REINDL, B., PIVAC, I. 2006: The spectrum of tusk pathology in wild boar (*Sus scrofa* L.) from Croatia. *Veterinarski Arhiv* 76 (Supplement), S91–S100.
- KYSELÝ, R. 2001: Přehled zvířecích kostí z arch. výzkumů v Lovosicích (Litoměřice). Unpublished report TP-2001-5258. Deposited: Archiv of Institute of Archaeology of the Academy of Sciences of the Czech Republic, Prague.
- KYSELÝ, R. 2003: Savci (Mammalia) z raně středověkého hradu Stará Boleslav (střední Čechy). In: Boháčová, I. (Ed.): *Stará Boleslav. Přemyslovský hrad v raném středověku. – Stará Boleslav. Přemyslid Stronghold in the early Middle Ages*. Mediaevalia archaeologica 5, 311–334.
- KYSELÝ, R. 2007: Osteologická analýza. In: Ernée, M., Dobeš, M., Hlaváč, J., Kočár, P., Kyselý, R., Šída, P.: *Zahloubená chata ze středního eneolitu v Praze 9 – Míškovicích. Výsledky archeologických a přírodovědných analýz. Památky archeologické* 98, 31–108.
- KYSELÝ, R. 2009: Zvířecí kosti z eneolitických objektů v Praze-Řáblicích, ul. Legionářů. *Archeologie ve středních Čechách* 13(1), 169–172.
- KYSELÝ, R. 2012: Paleoeconomika lengyelského období a eneolitu Čech a Moravy z pohledu archeozoologie. *Památky archeologické* 103, 5–70.
- MAGNELL, O., CARTER, R. 2007: The chronology of tooth development in wild boar – A guide to age determination of linear enamel hypoplasia in prehistoric and medieval pigs. *Veterinarija ir zootechnika* 40(62), 51–81.
- MILES, A. E. W., GRIGSON, C. 1990: *Colyer's variations and diseases of the teeth of animals*. Revised ed. Cambridge University Press, Cambridge.
- PALÁŠTHY, J., PALÁŠTHY, S. 1991: Klassifikation von Eckzahnmalen beim Wildschwein. *Zeitschrift für Jagdwissenschaft* 37(3), 195–203.
- PEŠKE, L. 1976: Praha – Vojanovy sady. Zpráva o rozboru osteologického material. Unpublished report TP-1976-1525. Deposited: Archive of Institute of Archaeology of the Academy of Sciences of the Czech Republic, Prague.
- PEŠKE, L. 1993: Osteological analysis of the material from Radovesice (23): Animal husbandry in La Tène period. In: Waldhauser J.: *Die Hallstatt- und Latènezeitliche Siedlung mit Gräberfeld bei Radovesice in Böhmen*. II Band. Archeologický výzkum v severních Čechách 21. Prague, 156–172.
- PIGIERE, F. 2009: *Évolution de l'économie alimentaire et des pratiques d'élevage de l'antiquité au haut moyen âge en Gaule du nord. Une étude régionale sur la zone limonuse de la moyenne Belgique et du sud des Pays-Bas*. British Archaeological Reports, International Series 2035. Archaeopress, Oxford.
- SALÁČ, V. 1990: K poznání laténského (LT C2-D1) výrobního a distribučního centra v Lovosicích – Zu Untersuchungen über ein latènezeitliches (LT C2-D1) Produktions- und Distributionszentrum in Lovosice. *Archeologické rozhledy* 42, 609–639.
- TEEGEN, W.-R., WUSSOW, J. 2000: Maltreatment of animals in the late 19th and early 20th century AD? Evidence from the Julius-Kühn-Collection, University of Halle-Wittenberg (Germany). Poster presentation, XIIIth European Meeting of the Paleopathology Association, Chieti, September 2000. *Journal of Paleopathology* 11(2), 199, 113.
- TEEGEN, W.-R. 2004: Hypoplasia of the Tooth Root: A New Unspecific Stress Marker in Human and Animal Paleopathology. *American Journal of Physical Anthropology, Supplement* 38, 193.
- TEEGEN, W.-R. 2005: Linear transverse enamel hypoplasias in medieval pigs from Germany: Starigard/Oldenburg (10th cent. AD). In: Davies, J., Fabiš, M., Mainland, I., Richards, M., Thomas, R. (Eds.): *Health and Diet in Past Animal Populations: Current research and future directions*. Proceedings of the 9th ICAZ Conference, Durham 2002. Oxbow, Oxford, 89–92.
- TEEGEN, W.-R. 2006: Zur Archäologie der Tierkrankheiten von der frühen Eisenzeit bis zur Renaissance im deutschen Küstengebiet. MS. Habilitation thesis. Deposited: Faculty of History, Arts and Oriental Sciences, University of Leipzig.
- TEEGEN, W.-R. 2010: Osteologische Untersuchungen. In: Miron, A., Miron, A. V. B., Sauer, D., Schrickel, M., Teegen, W.-R.: *Der Nahekopf bei Frauenberg (Kr. Birkenfeld). Bericht über die Ausgrabungen 2007*. *Trierer Zeitschrift* 71, 2008/09, 249–257, 259–266.
- TEEGEN, W.-R. 2013: So eine Schweinerei... Vergleichende Untersuchungen zum Stress bei eisenzeitlichen bis mittelalterlichen Schweinen aus dem norddeutschen Küstengebiet. *Siedlungs- und Küstenforschung im südlichen Nordseegebiet* 36, 53–62.
- TEEGEN, W.-R., PRILLOFF, R.-J. 2014: Die krankhaft veränderten Tierknochen aus dem spätmittelalterlichen Abfallschacht in der Grafengasse 2–6 in Erfurt. *Alt-Thüringen*, submitted.
- WAGENKNECHT, E. 1979: *Altersbestimmung des erlegten Wildes*. Fifth ed. J. Neumann-Neudamm, Melsungen.
- WALDHAUSER, J. 1993: Beschreibung der Befunde – Übersichtliche Darstellung der Funde. In: Waldhauser, J.: *Die Hallstatt- und Latènezeitliche Siedlung mit Gräberfeld bei Radovesice in Böhmen*. Archeologický výzkum v severních Čechách 21, 6–68.
- WILTSCHE-SCHROTTA, K. 1988: Das frühbronzezeitliche Gräberfeld von Franzhausen I. Analyse der morphologischen Merkmale mit besonderer Berücksichtigung der epigenetischen Varianten. MS. PhD thesis. Deposited: Faculty of Biology, University of Vienna, Vienna.
- WOLOCH, A. 2002: Wachstumsdynamik der Eckzähne des Schwarzwildes der südlichen Ukraine. *Zeitschrift für Jagdwissenschaft* 48(3), 186–193.